

RADIOACTIVE IODINE-125 SEED FOR LOCALIZATION OF BREAST CANCER LESIONS

Manny Subramanian, Rohit Mehta and Krishnan Suthanthiran

Best Medical International, Inc., 7643 Fullerton Road, Springfield, Virginia, 22153 USA

Iodine-125 seeds are primarily used in the treatment of localized prostate cancers. However recently, breast surgeons and interventional radiologists have found that these seeds can also be used for localization of non palpable breast lesions instead of wire localization. In this presentation, we provide a description of several formulations of iodine-125 seeds for successful use in breast localization studies. Loosely loaded seeds in 5 to 15 cm 18G needles as well as seeds loaded in tissue absorbable strands were useful for these applications. Seeds of activities ranging from 0.075 mCi per seed to 0.35 mCi per seed have been routinely used for these diagnostic procedures.

Iodine-125 seeds consist of Tungsten rods coated with carbon containing iodine-125, encapsulated in 5 mm titanium capsules (FIG. 1a and 1b).



FIGURE 1a:
Iodine-125 Seed



FIGURE 1b:
Length – 5 mm,
Outer Diameter – 0.8 mm

The carbon rods can be loaded with 20 uCi to up to 80 mCi per seed. A small amount of sodium iodide (I-125) solution is dropped onto the carbon coated on to a Tungsten rod (yellow cylinder in FIG. 1a) uniformly so that the entire rod is coated with a thin layer of iodine solution. These rods are dried under inert atmosphere, and then encapsulated in titanium capsules. The nominal dimensions of these seeds are: length 5 mm and outer diameter 0.8 mm. The capsules are then welded carefully with a laser beam to avoid any leakage of radioactive material. A leak test is performed at high temperature and pressure to determine any possible leak of iodine-125.

Dose measurement studies have been performed using TLDs to determine the dosimetry parameters of iodine-125 seeds. Furthermore, these seeds have been routinely sent to National Institute of Standards and Technology (NIST), Gaithersburg, Maryland and the absolute activity has been calibrated at regular intervals.

The radioactive seed is implanted by a radiation oncologist, nuclear medicine physician or interventional radiologist, prior to surgery either

with the help of mammography or ultrasound guidance. Because of the Tungsten rod, the seeds can also be visualized in radiography. The surgery is normally performed the same day or within 7 days of implantation of the seed. The surgeon, with the help of a probe device (e.g., NeoProbe) that is specifically designed to quantify the radioactive iodine-125 in the tissues, will determine the location of seeds and thereby the position of non-palpable lesions. The lesions containing the radioactive seed(s) are then removed and sent for pathological evaluation.

The handling of the seeds is performed in accordance with regulatory requirements. We also developed a stranding material made of a copolymer formulation that dissolves slowly in the tissue (FIG. 2a) over a period of several weeks. The strand dissolved in the tissue and this resulted in lack of migration of seeds. The seeds have been implanted as loose seeds or seeds loaded in tissue-absorbable strand material (FIG. 2b and 2c).




FIGURE 2a: Copolymer Strands



FIGURE 2b:
Loose Seed Loaded
into Needle



FIGURE 2c: Seed in
Tissue-Absorbable
Strand Material




FIGURE 2d: Breast Localization Needles
in 5, 7, 10 and 15 cm lengths

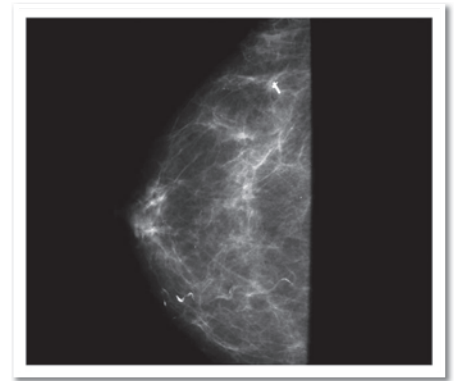


FIGURE 3: Preoperative Mammography
Confirming Seed Placement at the Clip

(Image courtesy of James W. Jakub, M.D., F.A.C.S., Mayo Clinic, Rochester, MN, USA)

Trials comparing intraoperative margin status and final margin status of wire-localized lumpectomies versus radioactive seed-localized lumpectomies and incidence of identifying the SLN during radioactive seed-guided lumpectomies

Study	Year	Wire (n)	First Intraoperative Margin Positive	Final Margin Positive	Seeds (n)	First Intraoperative Margin Positive	Final Margin Positive	SLN Identified (Seed Cases)
Grey et al.	2001	26	57%	NA	35	26%	NA	97%
Cox et al.	2003	NA	NA	NA	64	41%	27%	NA
Grey et al.	2004	79	46%	24%	83	26%	10%	100%
Hughes et al.	2008	99	46%	25%	383	27%	8%	100%

NA – Not Available

TABLE 1

Adapted from J.W. Jakub et al., Radioactive Seed-Localized Breast Surgery, The American Journal of Surgery, Vol.199, No.4, April 2010

Results obtained so far in the clinic in several institutions indicate that this is a viable option.

1. Radioactive seeds are easier to locate compared to wires. Hence often this method is more convenient to surgeons and interventional radiologists.
2. The implantation procedure is simple, less time consuming and can be performed in an out patient set up.
3. Compared to wires installed in patients, seeds are more comfortable to patients.
4. This methodology appears to be a safe and effective method for localization of breast cancer lesions.

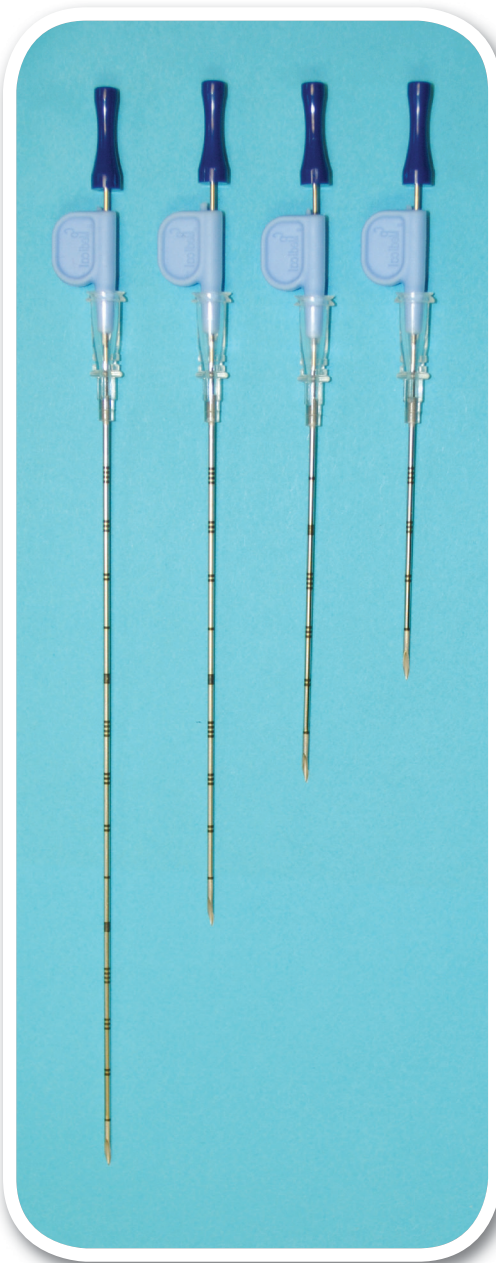References:

Ravinder Nath and Ning Yue, Dosimetric characterization of an encapsulated interstitial brachytherapy source of I-125 on a tungsten substrate, Brachytherapy 1,102-109 (2002).

Manny R. Subramanian, Krishnan Suthanthiran and Anotoli Dristchilo, "Radioactive Sources for Interstitial Brachytherapy" in 'Basic and Advanced Techniques in Prostate Brachytherapy', Dicker, A.P. et al., (Eds.), Taylor and Francis, London, 2005.

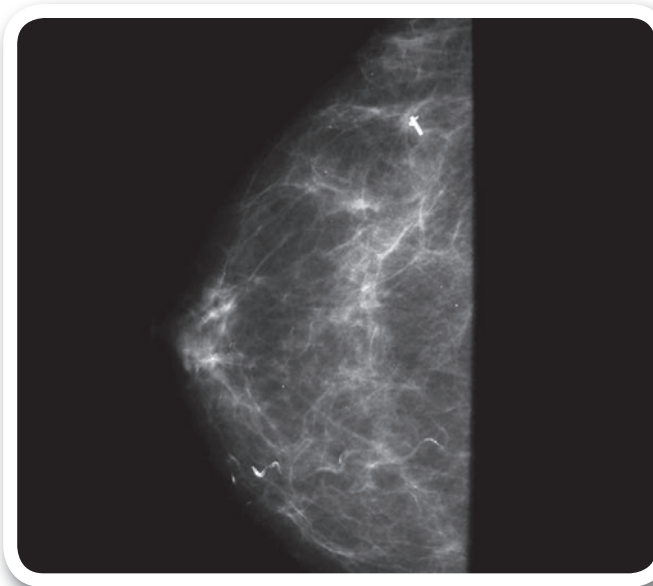
James Jakub, Richard Gray, Amy Degnim, Judy Boughey, Mary Gardner and Charles Cox, Current Status of radioactive seed for localization of non palpable lesions, Amer. J. Surgery, 199, 522-528 (2010).

Best Iodine-125 Seed for Breast Cancer Localization



Best Medical International supplies breast localization needles with Iodine-125 seeds

- Best localization needles are available in 5, 7, 10 and 15 cm lengths
- Available in various ranges of seed activities with a shelf life of 90 days
- Needles contain Iodine-125 seeds for localization of non-palpable lesions in breast cancers, and are used instead of surgical clips
- Needles are supplied sterile and are individually packaged and shielded



Preoperative Mammography Confirming Seed Placement at the Clip

Image courtesy of James W. Jakub, M.D., F.A.C.S., Mayo Clinic, Rochester, MN, USA

© 2018 Best Medical International, Inc.

Best Medical International, Inc. 7643 Fullerton Road, Springfield, VA 22153 USA
703 451 2378 800 336 4970 www.bestmedical.com www.teambest.com

AFRICA | ASIA | EUROPE | LATIN AMERICA | MIDDLE EAST | NORTH AMERICA

